

# Congenital Muscular Torticollis

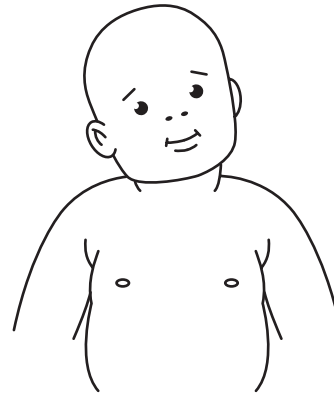
Congenital muscular torticollis (CMT) is due to tightness of a muscle in the neck called the sternocleidomastoid (SCM). It is usually noticed shortly after birth.

The incidence of CMT is reported as 3–20 in every 1000 births. The cause is unknown. There are a number of theories including the position of the baby in the womb, difficult delivery, and infection or injury to the blood vessels of the muscle.

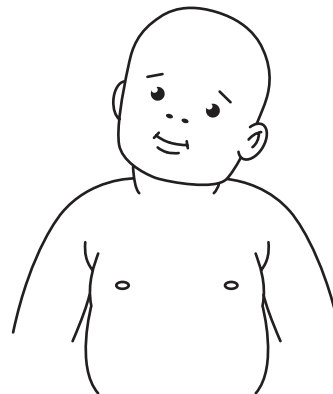
The baby tends to turn their head to only one side and their head is often tilted (**Figures 1,2**). A firm lump may be seen or felt within the muscle of the neck in the first 4 weeks after birth, and usually disappears within 6 months. The baby may develop flattening of the head on one side due to constantly resting their head in the same position. This is known as plagiocephaly.

The initial management of babies with CMT is physiotherapy. Physiotherapy treatment commenced before the baby is three months old is associated with a better outcome. Physiotherapy includes teaching parents gentle stretches for the baby's neck, which need to be performed several times a day. The physiotherapist will also give advice about play and carry positions to encourage the baby to actively correct their head and neck posture.

If torticollis persists, and does not respond to physiotherapy, surgical lengthening of the tight muscle may be necessary after 12 months of age.



**Figure 1.** Right torticollis with the right ear tilted to the right shoulder and the chin turned towards the left shoulder.



**Figure 2.** Left torticollis with the left ear tilted to the left shoulder and the chin turned towards the right shoulder.